



# Management of Hepatopulmonary Syndrome in a Child Due to a Large Congenital Intrahepatic Porto-Systemic Shunt

Chandan Kumar Kedarisetty<sup>1,\*</sup>, Rajeev Kamble<sup>2</sup>, Santhosh Joseph<sup>2</sup>, Jayanthi Venkataraman<sup>1</sup>

<sup>1</sup>Department of Hepatology, Sri Ramachandra Institute of Higher Education and Research, Chennai, India

<sup>2</sup>Department of Interventional Radiology, Sri Ramachandra Institute of Higher Education and Research, Chennai, India

## Email address:

drchandankn@gmail.com (C. K. Kedarisetty)

\*Corresponding author

## To cite this article:

Chandan Kumar Kedarisetty, Rajeev Kamble, Santhosh Joseph, Jayanthi Venkataraman. Management of Hepatopulmonary Syndrome in a Child Due to a Large Congenital Intrahepatic Porto-Systemic Shunt. *International Journal of Gastroenterology*.

Vol. 3, No. 1, 2019, pp. 23-26. doi: 10.11648/j.ijg.20190301.14

Received: August 17, 2019; Accepted: September 10, 2019; Published: September 24, 2019

**Abstract:** Background: Abernethy malformations are rare vascular anomalies of the portal system which present as extra-hepatic congenital portosystemic venous shunts (CPSS). Sometimes they can be intra-hepatic anomalies. There is scarcity of literature on management of these rare anomalies especially intra-hepatic shunts. Case: A five years old child came with the complaints of progressive breathlessness on exertion with effort-intolerance for the past two years. There was no history suggestive of underlying cardiopulmonary illness. On examination, there was cyanosis and clubbing. On evaluation, the imaging showed a large congenital intra-hepatic portosystemic shunt from the left portal vein draining directly into intrahepatic inferior vena cava (IVC) and a hypoplastic right branch of the portal vein leading to a clinical presentation of hepatopulmonary syndrome. Result: The shunt was occluded by placing a covered stent in the IVC across the shunt opening, making sure the openings of hepatic veins and renal vein also were not being covered. There was a significant improvement in oxygenation post procedure with complete disappearance of cyanosis. Conclusion: Covered IVC stent placement is a novel technique for large fusiform dilated intra-hepatic CPSS by closing the shunt flow into the IVC, thereby restoring the physiological flow in the liver.

**Keywords:** Clinical Decision Making, Computer Tomography, Development Genes, Hepatic Encephalopathy, Dyspnea

## 1. Introduction

Abernethy malformations are very rare vascular anomalies of the portal system with an overall incidence of 1:30,000 births [1]. These anomalies can also be intra-hepatic. Due to abnormal shunting of portal venous blood into the systemic circulation, there is a passage of vasoactive mediators from the splanchnic circulation directly into the pulmonary system bypassing the liver. This leads to intrapulmonary vascular dilatations and impaired oxygen exchange which results in hepatopulmonary syndrome (HPS) [2]. Porto-systemic encephalopathy and porto-pulmonary hypertension are other complications, frequently observed in children [3]. Characteristically, they do not develop features of portal hypertension.

## 2. Case Presentation

### 2.1. History of Presenting Illness

A five-year-old boy presented with two years of history of shortness of breath and fatigue with minimal exertion. There was also a lack of weight gain. There was no other history to suggest congenital heart disease, cystic fibrosis or childhood asthma. Born out of non-consanguineous marriage, delivered by cesarean section at 8 months of gestation, the child cried immediately after birth and discharged in a week's time from the hospital. No similar history was noted in the siblings.

### 2.2. On Examination

The child was poorly built and nourished with a body mass

index was 11.3 kg/m<sup>2</sup>. There was bluish discoloration of tongue and nails suggestive of central and peripheral cyanosis. Undescended testis was noticed on the right side. Resting oxygen saturation was 75% on room air, which reduced to 68% with exertion and improved to 95% with oxygen supplementation.

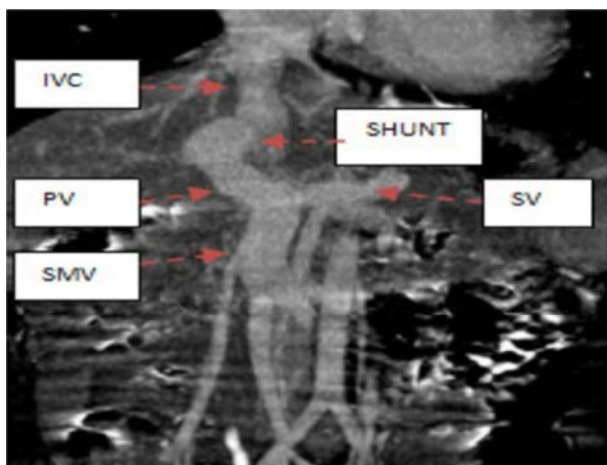
### 2.3. Investigations

#### 2.3.1. Laboratory Investigations

Showed normal blood counts, liver and kidney functions. Viral serology was negative.

#### 2.3.2. Radiological Investigations

- (i) Chest X-ray was unremarkable.
- (ii) Transthoracic echocardiography showed no structural anomaly, but bubble echo was positive for intra-pulmonary shunting.
- (iii) Pulmonary angiography was confirmative of diffuse pulmonary arteriovenous malformations. With no obvious cardiac congenital anomaly but echocardiogram and pulmonary angiogram been suggestive of hepatopulmonary syndrome, further evaluation was done to look for any sub-diaphragmatic anomalies.
- (iv) Ultrasound doppler of the abdomen showed normal-sized liver and normal hepatic veins. Interestingly, the portal system showed a dilated left portal vein draining directly into intrahepatic IVC and a hypoplastic right branch of the portal vein.
- (v) Subsequently, contrast-enhanced computed tomography abdomen was done which showed fusiform dilatation of left portal vein, measuring 13.2 mm in diameter, 32.4 mm in length and communicating with the intra-hepatic portion of IVC through an opening of 5.8 mm in diameter. The right portal vein was hypoplastic and spleen was normal (Figure 1). Institutional review board approval was obtained.



**Figure 1.** Coronal section of post-contrast abdominal CT in maximum intensity projection showing superior mesenteric vein (SMV), splenic vein (SV), portal vein (PV), inferior vena cava (IVC) and shunt relation.

## 3. Management

### 3.1. Methods

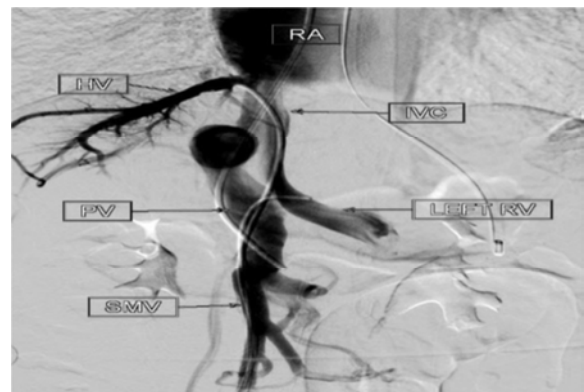
The treatment approaches were discussed in detail in a multidisciplinary board meeting involving interventional radiologists, hepatologists, pediatrician, liver surgeon, and anesthesiologist.

#### 3.1.1. Surgical Approach

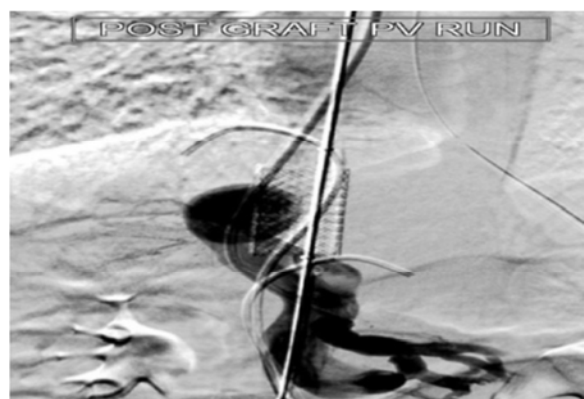
Liver resection was initially contemplated but later ruled as it would be a major hepatectomy with added risk of administering anesthesia in a hypoxemic child (due to HPS).

#### 3.1.2. Interventional Radiology Approach

It was the next best option. As it was large shunt, coil embolization would have been unsuccessful. Vascular plugs were also not considered as it was high flow large shunt through which the plug would have easily migrated into cardiopulmonary circulation. Finally, endovascular occlusion of the shunt by placing the covered stent graft in the IVC across the shunt opening with backup plans of using additional embolizing agents like vascular plugs, detachable and pushable coils and glue if required, was considered as the most feasible therapeutic option.



**Figure 2.** Digital subtraction angiographic runs taken simultaneously from portal vein (PV), hepatic vein (HV) and left renal vein (RV) showing relations between inferior vena cava (IVC), portal vein (PV) and superior mesenteric vein (SMV) with shunt between IVC and left branch of portal vein.



**Figure 3.** Post deploying IVC covered stent, portal venogram showed no contrast flowing from the intrahepatic shunt into the IVC but small intra-portal branches opacifying with contrast.

### 3.2. Procedure

Under general anesthesia, shunt closure was done by endovascular approach. Using ultrasound guidance, bilateral femoral veins and right internal jugular vein access were obtained and 5F sheaths were placed. Another 12F sheath was placed in the right femoral vein. Positions of the hepatic veins and left renal vein were noted and 5F cobra catheters were placed one each in the hepatic vein and left renal vein. The shunt between IVC and portal vein was cannulated by passing a multipurpose catheter from the right jugular sheath and positioned it within the superior mesenteric vein (Figure 2). Through the right femoral vein sheath, the diagnostic catheter with 035" Terumo wire was passed across the right atrium and positioned in the right subclavian vein. Subsequently, it was replaced with 035" exchange length Amplatz wire. Over this wire, Saline 14 x 30 mm covered stent graft was passed and deployed across the shunt avoiding covering the hepatic veins and renal vein. Angiographic runs taken after the deployment of graft revealed an absence of the flow across the intrahepatic portosystemic shunt with visible opacification of intrahepatic portal vein radicles (Figure 3). The portal pressure post stent deployment was measured to be around 5 mm Hg suggestive of no consequent portal hypertension.

### 3.3. Results

There were no immediate procedural complications. Post-procedure recovery was uneventful.

Follow up ultrasound doppler on 2nd and 4th day revealed no flow across the shunt with normal flow pattern in the portal vein and IVC with patent stent graft in the IVC.

The child was started on antiplatelets and discharged on 5th post op day. At the time of discharge, the child was symptomatically better with room air oxygen saturation maintained around 82 - 85%. The bluish hue in tongue and nails had also considerably decreased.

## 4. Discussion

CPSS can be either intrahepatic or extrahepatic. Usually, intrahepatic CPSS are classified into 4 types [4, 5]. Rarely, a patent ductus venosus originating from the left portal vein can present as intra-hepatic CPSS [6]. Patients with HPS present with dyspnea on exertion, cyanosis, and clubbing [7]. Due to the rarity of CPSS occurrence, the standard of care approach is not available. Interventional radiology procedures include coil embolization for small shunts [8] and use of vascular plugs for large high flow ones [9]. Surgical options [10, 11] include shunt ligation for extrahepatic CPSS, liver resection for large multifocal intrahepatic CPSS or focal malignant liver lesions or failed embolization and finally liver transplantation [12] for CPSS with complete agenesis of the portal vein. This child had a large intrahepatic CPSS which was not amenable to embolization or vascular plug insertion due to fear of migration. As CT angiography and portal venogram showed patent but atretic intrahepatic portal

vasculature, IVC covered stent placed was attempted to cover the shunt opening of CPSS into the IVC, thereby blocking the shunt flow into the systemic circulation. There is some interesting data that with successful closure of shunt, the hypoplastic intra-hepatic portal branches can also open and gradually restore the normal physiological portal flow [13]. During the procedure, careful mapping was done to avoid inadvertent placement of stent over the opening of hepatic veins or left renal vein opening into the IVC. Post-deployment of the stent, portal venogram showed no flow across the shunt into the IVC, with visualization of some intrahepatic portal vasculature. There is a similar case report [14] of an IVC covered stent deployment in an adult with extrahepatic Type II CPSS presenting with HPS. Another interesting case of extrahepatic Type II in a child with HPS was reported [15], where the authors utilized the concept of hepatic plasticity and had done three staged endovascular procedure, the first stage being IVC graft to block the portocaval fistula and transjugular intrahepatic shunt (TIPS) placement to control the consequent portal hypertension. Subsequent two stages being gradual reduction and closure of the TIPS stent till normal portal venous circulation is restored in the liver. In our case, it was a large intrahepatic shunt which was diverting blood into the IVC bypass the first pass metabolism in the liver. Hence, directly closing the shunt was the best option. Portal pressure was 4 mm Hg prior to stent deployment and 5 mmHg after deployment.

## 5. Conclusions

To the best of our knowledge, this is the first time, that a similar procedure of placement of covered IVC stent has been done in a large fusiform dilated intrahepatic portosystemic shunt malformation or patent ductus venosus in a child, which led to amelioration of HPS. At six months post procedural follow up, the child is doing well and free of any complications. Resting oxygen saturation is 96% and post-exercise saturation of 92%. He also demonstrated significant improvement in his physical activity and started going to school.

## 6. Recommendations

Abernethy malformations is an interesting but rare entity, which once identified, needs to be managed in a personalized approach, that will benefit the patient clinically. Newer techniques should be employed to detect this rare entity in antenatal period itself.

## Author Contributions

CKK and JV identified the patient's clinical condition and made the treatment strategy with SV and RK. The procedure was done by SV and RK. Follow up of the patient, drafting of the manuscript was done by CKK, critical revision of manuscript done for important intellectual content done by JV; administrative and technical support by JV.

## Abbreviations

IVC	inferior vena cava
CPSS	congenital portosystemic venous shunts
HPS	hepatopulmonary syndrome
TIPS	transjugular intrahepatic portosystemic shunt

## References

- [1] Bernard O, Franchi-Abella S, Branchereau S, Pariente D, Gauthier F, Jacquemin E. Congenital portosystemic shunts in children: recognition, evaluation, and management. *Semin Liver Dis* 2012; 32 (4): 273–287.
- [2] Alvarez A E, Ribeiro A F, Hessel G, Baracat J, Ribeiro J D. Abernethy malformation: One of the etiologies of hepatopulmonary syndrome. *Pediatr Pulmonol* 2002; 34: 391-4.
- [3] Sokollik C, Bandsma RH, Gana JC, van den Heuvel M, Ling SC. Congenital portosystemic shunt: characterization of a multisystem disease. *J Pediatr Gastroenterol Nutr* 2013; 56: 675–681.
- [4] Park JH, Cha SH, Han JK, Han MC. Intrahepatic portosystemic venous shunt. *Am J Roentgenol* 1990; 155: 527-528.
- [5] Ghuman SS, Gupta S, Buxi TBS, Rawat KS, Yadav A, Mehta N, Sud S. The Abernethy malformation – myriad imaging manifestations of a single entity. *Indian J Radiol Imaging* 2016; 26: 364-72.
- [6] Senocak E, Oğuz B, Edgüer T, Cila A. Congenital intrahepatic portosystemic shunt with variant inferior right hepatic vein. *Diagn Interv Radiol* 2008; 14: 97-99.
- [7] Zhang J and Fallon MB. Hepatopulmonary syndrome: update on pathogenesis and clinical features. *Nat Rev Gastroenterol Hepatol* 2012; 9: 539-549.
- [8] Yoshimatsu R, Takeuchi Y, Morishita H, Iida N, Okabe H, Yamagami T, Nishimura T. Successful embolization of intrahepatic portosystemic venous shunt using coils and n-butyl cyanoacrylate through two approach routes. *Br J Radiol* 2006; 79 (947): e162-5.
- [9] Power AH, Bjarnason H. Large spontaneous intrahepatic portal- systemic venous shunt treated with coil and Amplatzer vascular plug embolization. *Perspect Vasc Surg Endovasc Ther* 2012; 24 (2): 90–94.
- [10] Matsuura T, Takahashi Y, Yanagi Y, et al. Surgical strategy according to the anatomical types of congenital portosystemic shunts in children. *J Pediatr Surg* 2016; 51 (12): 2099-2104.
- [11] Sanada Y, Urahashi T, Ihara Y, Wakiya T, Okada N, Yamada N et al (2012 Mar) The role of operative intervention in management of congenital extrahepatic portosystemic shunt. *Surgery* 151 (3): 404-411.
- [12] Gordon-Burroughs S, Balogh J, Weiner MA et al. Liver transplantation in an adult with adenomatosis and congenital absence of the portal vein: a case report. *Transplant Proc* 2014; 46 (7): 2418-2421.
- [13] Shiomi S, Kuroki T, Ueda T et al. Clinical usefulness of evaluation of portal circulation by per-rectal portal scintigraphy with technetium-99m pertechnetate. *Am J Gastroenterol* 1995; 90: 460-5.
- [14] O'Leary JG, Rees CR, Klintmalm GB, Davis GL. Inferior vena cava stent resolves hepatopulmonary syndrome in an adult with spontaneous inferior vena cava-portal vein shunt. *Liver Transplantation* 2009; 15: 1897-1900.
- [15] Kuo MD, Miller FJ, Lavine JE, Peterson M, Finch M. Exploiting phenotypic plasticity for treatment of hepatopulmonary syndrome in Abernethy malformation. *J Vasc Interv Radiol* 2010; 21: 917-922.